

Foetal Hydrocephalus in a Cross Bred Cow: A Case Report

Thangamani A.*, Srinivas M., Chandra Prasad B., Sadasiva Rao K.

Department of Veterinary Gynaecology and Obstetrics, NTR College of Veterinary Science, Sri Venkateswara Veterinary University, Gannavaram-521102, Andhra Pradesh, India

Abstract

A case of dystocia due to foetal hydrocephalus in a cross bred cow calf and its successful obstetrical management has been reported.

Keywords: Dystocia, foetal hydrocephalus, cross bred cow

*Author for Correspondence E-mail: thangamtamil19@gmail.com

INTRODUCTION

Hydrocephalus is a dropsical condition of the foetus, accumulation of fluid which may be in ventricular system or between the brain and duramater. This condition is most commonly reported in pigs, puppies and calves [1]. The present case reports dystocia due to foetal hydrocephalus in a cross bred cow.

CASE HISTORY AND OBSERVATION

A cross bred cow aged 6 years in its third gestation was presented to the obstetrical unit, NTR CVSC, Gannavaram with the history of labour pain since 3 h without progress in expulsion of foetus. The both forelimbs of the foetus extended into the vulva but application of traction by the owner was futile. Pervaginal examination revealed completely dilated cervix with the dead foetus in anterior longitudinal presentation, dorso-sacral position, both forelimbs extended into the birth canal and head was abnormally enlarged with fluid feeling on palpation. So, the case was diagnosed as dystocia due to foetal hydrocephalus.

TREATMENT AND DISCUSSION

The perineal area of the cow was washed with antiseptic solution. Epidural analgesia was induced with 5 ml of 2% Lignocaine hydrochloride into the sacro-coccygeal space to reduce the straining. To remove the fluid, the enlarged part of the foetal head was punctured by using the obstetrical sharp hook. 6l of clear watery fluid was drained. Obstetrical snare were applied on the both extended forelimbs followed by obstetrical

hook applied on the left inner canthus of the foetal eye. Dead female foetus was removed by judicious manual traction (Figure 1). The examination of the foetus revealed fluid accumulation in the sub-dural space.

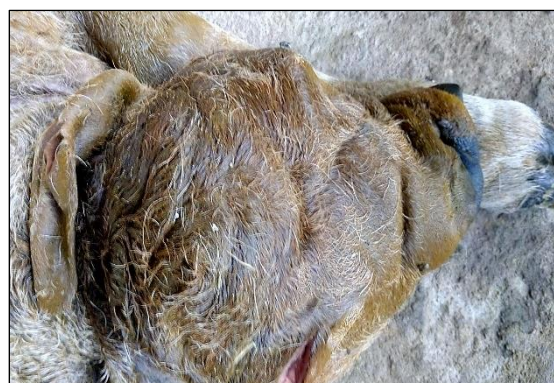


Fig. 1: Foetal Hydrocephalus.

Hydrocephalus is excessive accumulation of fluid in duramater or ventricles structure of the brain. Congenital hydrocephalus is reported in cattle [2]. Intra-uterine infection of the foetus may prone for hydrocephalus condition [3]. The foetuses are delivered by either excision of the fluid filled area of head followed by traction [4] or caesarean section [5]. In this present case, the foetus was delivered by excision of the fluid filled area of head by using sharp obstetrical hook followed by manual traction. Post-obstetrically the cattle was administered with DNS (5 l, i/v), Meloxicam (15 ml, i/m), Oxytocin (25 IU, i/v), Calcium borogluconate (350 ml, i/v) followed by inj. Streptopenicilin (5 gm, i/m). Antibiotic alone continued for three more days. The animal recovered uneventfully.

Summary

Dropsical condition of foetus has always been challenging to the field veterinarians. Cephalotomy procedure was required when large amount of fluid volume accumulated in the ventricles of the brain. The present case is recorded as a cause of dystocia due to foetal hydrocephalus in cow and its successful per-vaginal delivery.

REFERENCES

1. Arthur GH, Noakes DE, Parkinson TJ, et al. *Veterinary Reproduction and Obstetrics*. 7th Edn. London, England: WB Saunders Company Ltd.; 1996.
2. Sharda R, Ingole SP. Congenital Bilateral Hydrocephalus in Jersey Cow Calf. A Case Report. *Indian Vet J*. 2002; 79: 965–66p.
3. Konno S, Moriwaki M, Nakagawa M. Akabane Disease in Cattle. *Vet Pathol*. 1982; 19(3): 271–272p.
4. Prakash S, Selvaraju M, Ravikumar K, et al. Obstetrical Management of Foetal Hydrocephalus in a Kangeyam Cow. *Indian Vet J*. 2016; 93(09): 85–86p.
5. Bugalia NS, Chander S, Chandolia RK, et al. Mostrosities in Cows and Buffaloes. *In Vet J*. 1990; 67(11): 1042–1043p.

Cite this Article

Thangamani A, Srinivas M, Chandra Prasad B et al. Foetal Hydrocephalus in a Cross Bred Cow: A Case Report. *Research & Reviews: Journal of Veterinary Science and Technology*. 2018; 7(1): 1–2p.