

## Dystocia Due to Foetal Anasarca in Nellore Sheep: A Report of 5 Cases

*K. Ramachandria, C. Pavan Kumar\*, V. Devi Prasad*

Department of Veterinary Medicine, College of Veterinary Science, Proddatur,  
YSR Kadapa, Andhra Pradesh, India

### **Abstract**

*Five Nellore ewes were presented to veterinary hospital with history of dystocia with full term pregnancy. As field veterinarian handled it with traction and failed, caesariotomy was conducted as per the procedure and the oversized fetuses were delivered. The ewes were maintained post-operative measures and recovered. All the delivered fetuses were showing conditions of foetal anasarca along with other anomalies like cleft palate, reduced body cavity short legs and atresia ani.*

**Keywords:** *Dystocia, nellore sheep, foetal anasarca, caesariotomy, cleft palate*

\***Author for Correspondence** E-mail: pavancvet@gmail.com

### **INTRODUCTION**

There is an increasing demand for mutton and chev on over the last two decades. This makes the sheep and goat farming commercial enterprise. Now there are organized sheep and goat farms all over the India. Earlier sheep and goat with dystocia were either salvaged at throw away prices or slaughtered. As the prices of these small ruminants are sky rocketed, more attention is paid towards the healthcare of these species. Dystocia in sheep can be better treated by caesarian section with comparatively very good prognosis. The incidence of dystocia varies between 8 and 50% [1]. Mutational operations often fail due to little working space. Dystocia may be due to maternal causes like small sized pelvis, primary or secondary uterine inertia, ring womb etc. The foetal causes include anasarca, gygantism, polycertia and monsterties etc. [2].

Available literature showed a few reports on fetal anasarca in sheep and in goats [3–6]. The present paper communicates five cases of dystocia due to foetal anasarca in Nellore sheep and their surgical correction through cesaeriotomy in ewes.

### **HISTORY CLINICAL OBSERVATIONS**

Five (5) Nellore ewes were presented to veterinary ploy clinic with a history of

dystocia referred by local veterinarians completing gestation period, straining, discomfort and ruptured water bag. On examination abdomen was distended abnormally in all the cases. Per-vaginal examination revealed fetuses in anterior presentation with fore legs and head extended in to birth canal (Figure 1). All the vital parameters were within the normal range. Treatment with calcium borogluconate and ringers lactate and dexamethasone could not relieve dystocia. Traction applied to relieve dystocia also in vain and cesaeriotomy was under taken in these cases.

Animals were prepared for aseptic surgery. Local analgesia was achieved by local infiltration of 2% lignocain HCl around the site of incision. Skin abdominal muscles and peritoneum were incised through left flank incision. Due to growth of oversized fetuses, exteriorization of the gravid uterus was not possible. Hence after through packing of abdominal cavity with laporotomy sponges or sterile surgical towels, hysterotomy was performed and fetuses were delivered (Figure 2). The uterus was thoroughly irrigated with sterile normal saline and was closed by double invasion technique (Cushings followed by Lambert) using chromic catgut no. 0. The peritoneum and muscle layers were sutured together by ford's interlocking suture. Skin edges were approximated by cross

mattress pattern using braided black silk. Tincture benzoin seal was applied over the suture line. Post-operatively animals were kept on Ceftriaxone @ 10 mg/KgBwt (Intacef<sup>®</sup>) I/M, Meloxicam @ 0.5 mg/kgBwt (Melonex<sup>®</sup> 2 ml) I/M, and Tribivet<sup>®</sup> @ 2 ml, I/M were given for 5 days. Skin sutures were removed on 10<sup>th</sup> post-operative day.

Foetuses in all the five (5) cases had more or less bull dog appearance (Figure 3) when kept in sternal recumbency. The weight of the fetuses ranged from 8 to 13 kgs. The gross oversize of the fetuses was due to diffuse (Anasarca) generalized oedema. Upon dissection of the specimens other concomitant congenital anomalies were identified. These included cleft palate (n=2) (Figure 5), narrow body cavities (n=2) (Figure 4) and atresia ani (n=1) etc.

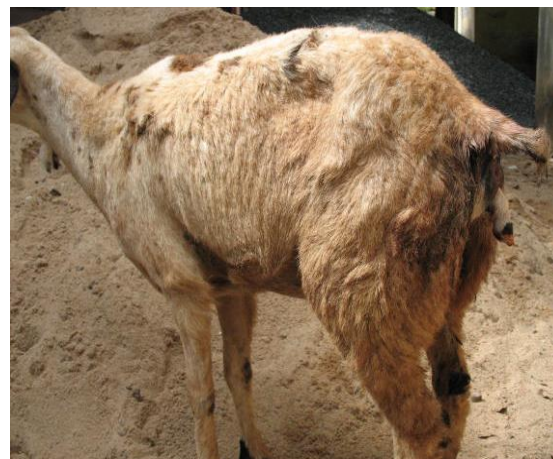
## RESULTS AND DISCUSSION

In all the five cases there was enormous distension of the abdominal cavity which was confused with twins and triplets in the uterus. There were no abnormalities regarding presentation, position and posture. The abnormal weight of the fetuses was due to dropsy contributing to 20–30% of the weight of the dams.

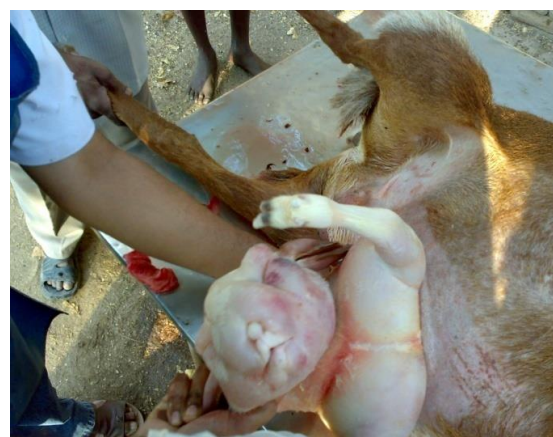The etiology of most of the foetal gestational complications except abortions continues to be poorly understood [5]. However, it is attributed that the probable cause of foetal anomalies to hereditary predisposition due to autosomal recessive gene [7]. The parity of the animals in the present report ranged from 2 to 6. Similar observations were also observed by some researchers who observed foetal gigantism when the litter size was small but the size of individual fetuses was large [8–10].

A complete cleft in the maxilla is developmental anomaly independent of anasarca which can be attributed to autosomal recessive gene. The important incremental factors were prenatal viral infections, intra uterine foetal exposure to poisons ingested by dam, vitamin A and folic acid deficiency; hyperthermia and mutations [11]. It is opined that 21.9% of sheep responded efficiently to PGF2 $\alpha$ . As the animals were presented in advanced conditions with post maturity

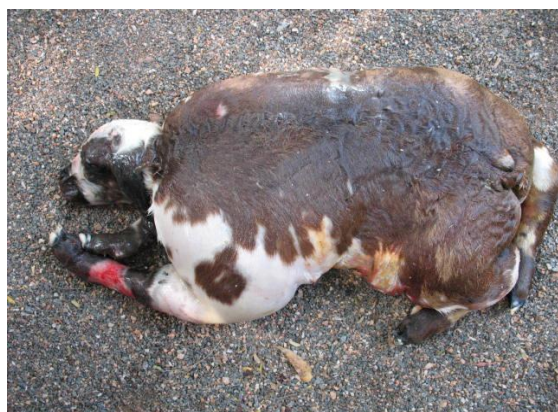changes and hence hormonal therapy was not tried in these cases and caesarian section was resorted [2]. It appears that the incidence of foetal anomalies is increasing in these days. In the current study as 5 out of 22 cases over a period of 1 year accounting for 22.7% recorded as congenital anomalies. Contrary to these findings 1.9% of incidence was observed over a period of 11 years in newborn Awassi lambs [12]. Increase in the number of cases of dystocia reported for the treatment could have been the cause of this increase in incidence. All the dams recovered uneventfully following caesarian section and were observed to conceive normally in the subsequent lambings. It can be inferred that timely surgical intervention in all these cases would have saved the lambs. Similar high success rate with caesarian section (96.2%), followed by traction and manual correction (85.9%) whereas success of 57.1% without assistance was reported [13].



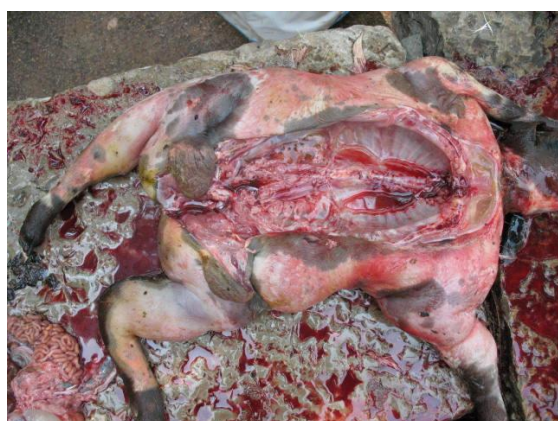*Fig. 1: Ewe Straining with Fore Limb in the Vagina.*



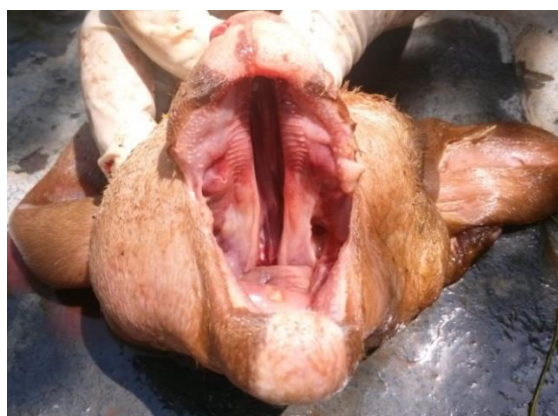
*Fig. 2: Delivering the Anasarca Foetus from Uterus.*



**Fig. 3:** Bull Dog Lamb Associated with Foetal Anasarca.



**Fig. 4:** Dissected Foetus with Narrow Body Cavities.



**Fig. 5:** Cleft Palate in Foetus.

## REFERENCES

1. Purohit GN. Distocia in sheep and goats-A review. *Indian Journal of Small Ruminants*. 2006; 12(1): 1–12p.
2. Ali AHM. Causes and management of dystocia in small ruminants in Saudi Arabia. *Journal of Agricultural and Veterinary Science*. 2011; 4(2): 95–108p.
3. Hailat N, Lafi SQ, Al-Darraj A, et al. Foetal Anasarca in Awassi sheep. *Aust Vet J*. 1997; 75(4): 257– 259p.
4. Saxena A, Rahim A, Chandra R, et al. Surgical intervention in certain reproductive disorders of goat. *Intas Polivet*. 2001; 1: 57–61p.
5. Philip LM, Mohan MR, Bastiin FP. Fetal anasarca twins with hydroallantois in malabari does. *J.Ind.Vet.Assoc*. 2012; 10(1): 52–53p.
6. Jayachandra HK, Kulkarni H, Magadam S, et al. Dystocia due to foetal anasarca with achandropasia in a goat-A case report. *International Journal of Food, Agriculture and Veterinary Sciences*. 2013; 3: 116–118p.
7. Arthur GH, Noakes DE, Pearson H, et al. Dystocia and other disorders associated with parturition. *Veterinary reproduction and obstetrics*. 1996; 110–192p.
8. Rahim AT, Arthur GH. Obstetrical conditions in goats. *Cornell Veterinarian*. 1982; 72(3): 279–284p.
9. Jackson PGG. *Hand book of Veterinary obstetrics*. 2nd edition. Saunders, London; 2004.
10. Noakes DE, Parkinson TJ, England GCW. *Arthur's Veterinary reproduction and obstetrics*. 9th edition. Saunders, Edinburg, London; 2009.
11. Jones TC, Hunt RD, King NW. *Veterinary pathology*. Williams and Wilkins, Baltimore, USA; 1997.
12. Elias E, Bennet R. Congenital defects in Awassi fat tailed lambs. *Small Rumin Res*. 1992; 8(1–2): 141–150p.
13. Majeed AF, Taha MB. Dystocia in local goats in Iraq. *Small Ruminant Research*. 1989; 2(4): 375–381p.

### Cite this Article

K. Ramachandriah, C. Pavan Kumar, V. Devi Prasad. Dystocia Due to Foetal Anasarca in Nellore Sheep – A Report of 5 Cases. *Research & Reviews: Journal of Veterinary Science and Technology*. 2015; 4(1): 17–19p.